Case Report

CNS Oncology

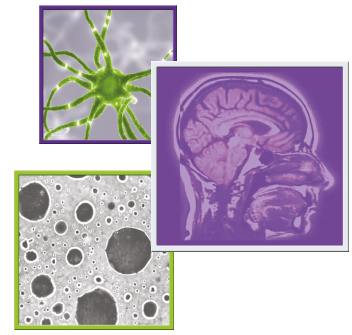

Ivosidenib, an IDH1 inhibitor, in a patient with recurrent, *IDH1*-mutant glioblastoma: a case report from a Phase I study

Dalissa Tejera[1,2], Marina Kushnirsky[1], Sakir H Gultekin[3], Min Lu[4], Lori Steelman[4] & Macarena I de la Fuente*[,1,2]

[1]Department of Neurology, University of Miami, Miami, FL 33136, USA
[2]Sylvester Comprehensive Cancer Center, University of Miami, Miami, FL 33136, USA
[3]Department of Pathology, University of Miami, Miami, FL 33136, USA
[4]Agios Pharmaceuticals, Inc., Cambridge, MA 02139, USA
*Author for correspondence: Tel.: +1 305 243 4951; Mdelafuente@med.miami.edu

Glioblastoma is the most common and aggressive primary brain tumor. Despite standard multimodality therapy, median overall survival remains poor with a 5-year survival rate of approximately 5% in most studies (range 4.7–13.0%). Strong interest in targeting IDH mutations has led to a variety of studies in both hematologic malignancies and solid tumors and to the approval of IDH inhibitors such as ivosidenib, an IDH1 inhibitor, in hematologic malignancies. Here, we present the first case study of a patient with a recurrent *IDH1*-mutant glioblastoma who experienced improved seizure control and radiographic stable disease for more than 4 years while treated with ivosidenib. Such findings support the further development of IDH inhibitors as single agents and/or in combination for the treatment of *IDH*-mutant glioma.

First draft submitted: 8 June 2020; Accepted for publication: 30 June 2020; Published online: 27 July 2020

Keywords: glioblastoma • *IDH1*-mutant • IDH inhibitor • IDH mutation • ivosidenib • low-grade glioma • targeted therapy

Background

Glioblastoma (GBM) is the most common and aggressive malignant primary brain tumor, accounting for 48% of all malignant primary central nervous system (CNS) cases [1]. Standard-of-care treatment for newly diagnosed GBM consists of maximal safe surgical resection, followed by radiotherapy with concurrent temozolomide and six adjuvant temozolomide cycles with or without alternating tumor-treating fields therapy [2,3]. Despite this multimodality treatment, tumors consistently recur and median overall survival (OS) remains poor at 15–21 months, with approximately 5% surviving for 5 years in most studies (range 4.7–13.0%) [1–4].

The expanding knowledge of the molecular basis of cancer and ability to target cancer cells based on tumor-specific molecular alterations have made a significant impact in the management and survival of patients with different tumor types. A mutation in the gene encoding the metabolic enzyme IDH1 was first identified in colorectal cancers in 2006 [5]. In 2008, a genome-wide mutation analysis identified somatic mutations in *IDH1* in 12% of GBMs [6]. Subsequently, it was confirmed that *IDH1* was mutated in up to 7% of GBMs and in over 70% of grade II and grade III gliomas [7,8]. Mutations were also identified in the *IDH2* gene in approximately 4–8% of gliomas [8]. Since then, *IDH1* and *IDH2* mutations have been identified in multiple other cancers, such as chondrosarcoma, intrahepatic cholangiocarcinoma and acute myeloid leukemia (AML) [9–12]. These molecular alterations were incorporated into the WHO (Geneva, Switzerland) classification of CNS tumors in 2016 for the first time, demonstrating the clinical prognostic of these mutations and their impact on survival [13].

In glioma, it has been well established that *IDH* mutation is an early event in gliomagenesis and that mutant *IDH* cooperates with other oncogenic events, such as missense mutations in *ATRX* and *TP53* in astrocytomas or codeletions of chromosome arms 1p and 19p in oligodendrogliomas, to initiate cancer [14,15]. However, whether the role of the mutant IDH enzyme remains important for the growth of fully established *IDH*-mutant gliomas is yet to be determined.

Future Medicine

The IDH family includes three different isoforms of IDH (IDH1, IDH2 and IDH3) that catalyze the oxidative decarboxylation of isocitrate to produce α-ketoglutarate while reducing $NADP^+$ to NADPH – or nicotinamide adenine dinucleotide to nicotinamide adenine dinucleotide hydrogen in the case of IDH3. This is one of the rate-limiting steps of the tricarboxylic acid cycle, playing an important role in normal cellular metabolism and in protection against oxidative stress and apoptosis. The R132 residue is located within the active site of IDH1 and forms hydrogen bonds with the isocitrate substrate [8,16]. The R172 residue in IDH2 is the exact analogue of the R132 residue in IDH1 [16]. Substitutions at this location in the active site alter the enzymatic activity of IDH, resulting in the conversion of α-ketoglutarate to the oncometabolite, 2-HG, which is considered the effector of the downstream changes associated with tumorigenesis, including genome-wide CpG island hypermethylation, increased dsDNA breaks, decrease in $NADP^+$, and inhibition of α-ketoglutarate-dependent enzymes resulting in dysregulation of epigenetic and gene expression profiles [17–19].

Over the last decade, there has been a strong interest in targeting these mutations in both hematologic malignancies and solid tumors, including gliomas. This has led to the US FDA (MD, USA) approval of enasidenib (AG-221, an IDH2 inhibitor) and ivosidenib (AG-120, an IDH1 inhibitor) for adult patients with AML [20–22]. Ongoing trials are investigating the role of IDH inhibitors in solid tumors, including gliomas. Here, we present the first case study of a patient with a recurrent *IDH1*-mutant GBM who had radiographic stable disease for over 4 years and improved seizure control while treated with the IDH1 inhibitor ivosidenib.

Case report

The patient is a 28-year-old, Hispanic female who initially presented with headaches and focal seizures with impaired awareness. Her seizures lasted 1–2 min, with a postictal state of 15–20 min at a frequency of 2–3 per month, despite lacosamide 150 mg twice daily and levetiracetam 1750 mg twice daily. Brain MRI revealed a left frontal, T2 hyperintense lesion, measuring 4.5 × 2.8 × 4.3 cm with faint enhancement. She underwent gross total resection with pathology read as *IDH1*-mutant WHO grade IV GBM. There were no Rosenthal fibers, eosinophilic granular bodies, ependymal or oligodendroglial features (Figure 1), and the sample was negative for 1p19q codeletion and *PTEN* deletion by fluorescence *in situ* hybridization. A next-generation sequence-based assay (FoundationOne® CDx by Foundation Medicine, MA, USA) showed that her tumor cells tested positive for the following genomic alterations: *IDH1* R132H, *TP53* R342, *ATRX* W2275 and *GLI1* R380Q. The following variants were of unknown significance: *BCORL1* D94N, *BLM* D1080A, *CREBBP* Q2318P, *FBXW7* D362V, *MLL2* T2203M, *MLL3* K3719I and *NOTCH1* P832L. The tumor cells tested negative for MGMT promoter hypermethylation status; DNA was extracted from a formalin-fixed paraffin-embedded specimen and bisulfite treated, pyrosequencing was performed using the PyroMark Q24 system and reagents provided by Qiagen (Venlo, Netherlands).

Seizure control improved immediately after resection, with a reduction in frequency (from about 3 to 1 per month) and duration and a change in quality from focal onset with impaired awareness to focal aware seizure. The patient then completed radiation therapy for a total of 60 Gy in 30 fractions over 6 weeks with concurrent temozolomide (75 mg/m^2 daily), followed by four adjuvant cycles of temozolomide (first cycle at 150 mg/m^2, followed by three cycles at 200 mg/m^2 daily for 5 days on/23 days off). The patient developed neutropenia during her adjuvant temozolomide cycles and required growth factor supportive therapy.

The patient had a follow-up MRI at her cycle 5 day 1 visit that revealed a new focal enhancement at the high left frontal surgical bed measuring 7.5 × 7.5 mm. She received one additional cycle of temozolomide and had a follow-up MRI one month after, which revealed further enlargement of the new enhancing lesion measuring 11.5 × 11 mm. The patient also had increased seizure frequency at that time. As the lesion was considered unresectable, the patient underwent tumor biopsy to confirm/rule out tumor progression, followed by laser interstitial thermal therapy (LITT). Pathology was read as WHO grade IV GBM. Next-generation sequencing testing failed due to insufficient tissue. Tumor cells again tested negative for MGMT promoter hypermethylation status by pyrosequencing. She signed a written informed consent form for the Phase I study of the IDH1 inhibitor ivosidenib in patients with advanced solid tumors, including glioma (NCT02073994). The patient was part of the expansion cohort of the study, treated at a 500 mg oral daily dose in continuous 28-day cycles. She was treated on study for over 4 years with radiographic stable disease (Figure 2) per response assessment in neuro-oncology criteria without any significant side effects, aside from grade 1 fatigue and grade 1 anorexia. She had no evidence of QT prolongation or liver toxicity while on study. The patient remains on anti-epileptic drugs but did not present with any further seizures. She was able to drive again and got back to work.

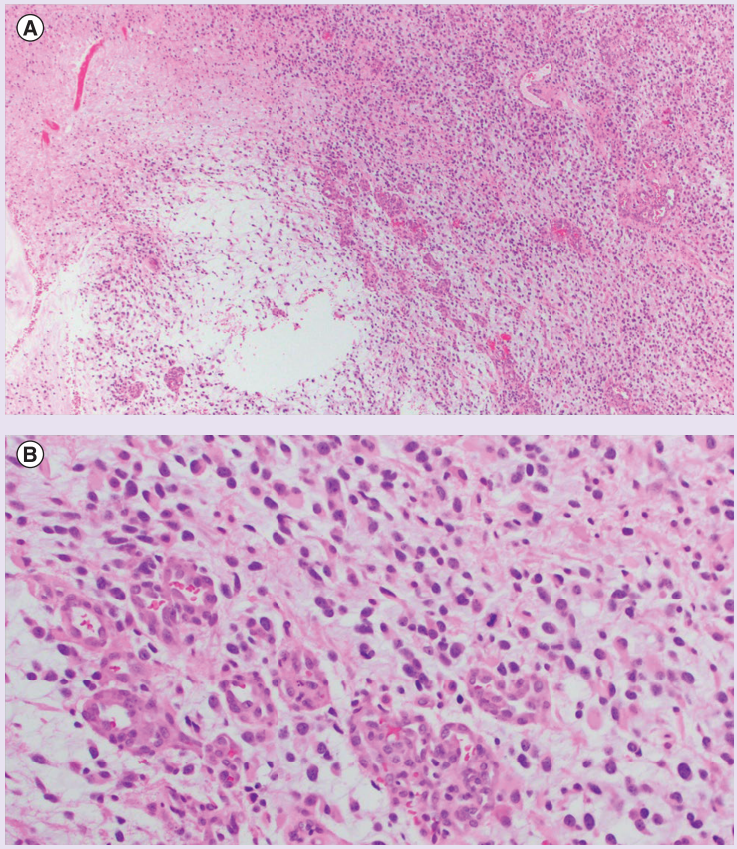

Figure 1. Histologic features at tumor diagnosis. (A) Hematoxylin/eosin staining (40×). Tumor sample demonstrating an atypical cellular glial neoplasm with an astrocytic phenotype, necrosis and vascular proliferation. **(B)** Hematoxylin/eosin staining (200×). Tumor sample demonstrating vascular proliferation and mitotic figure.

After 4 years and 1 month on the study, the patient presented with clinical and radiographic progression of disease. She discontinued study medication and was treated with re-irradiation. Five years and 2 months after initial diagnosis, the patient is alive and is currently being treated with bevacizumab.

Discussion

Although *IDH* mutations in GBM have been demonstrated to significantly prolong OS independently of other established prognostic factors, median OS for this patient population remains poor at 30–36 months [23–26]. MGMT promoter hypermethylation is usually present in *IDH*-mutant tumors. However, in this case, testing at diagnosis and at tumor progression showed it was unmethylated. OS is even lower in MGMT-unmethylated, *IDH*-mutant GBM when compared with MGMT-methylated, *IDH*-mutant GBM [26]. Despite significant advances in molecular characterization and classification of gliomas over the last decade, very limited improvement has been translated in terms of patient's outcome and survival. Furthermore, targeted therapy and immunotherapy outcomes in GBM have been particularly disappointing [27,28].

Ivosidenib is a targeted, potent, oral inhibitor of the mutant IDH1 protein [29]. Preclinical studies showed that treatment with ivosidenib decreased intracellular 2-HG level in *IDH1*-mutant AML cells *in vitro* [30], and resulted in >84% 2-HG inhibition in human *IDH1*-mutant brain tumors in a xenograft mouse model [31]. In a Phase I, perioperative study of ivosidenib and vorasidenib (AG-881, a dual IDH1/2 inhibitor) in recurrent *IDH1*-mutant, low-grade glioma, both drugs demonstrated CNS penetration and lowered 2-HG level >90% in tumor tissue compared with untreated samples [32]. Ivosidenib and vorasidenib showed a manageable safety profile [32].

To the best of our knowledge, this is the first case report on an *IDH*-mutant GBM treated with an IDH inhibitor. The patient was treated as part of a Phase I, multicenter, open-label, dose escalation and expansion

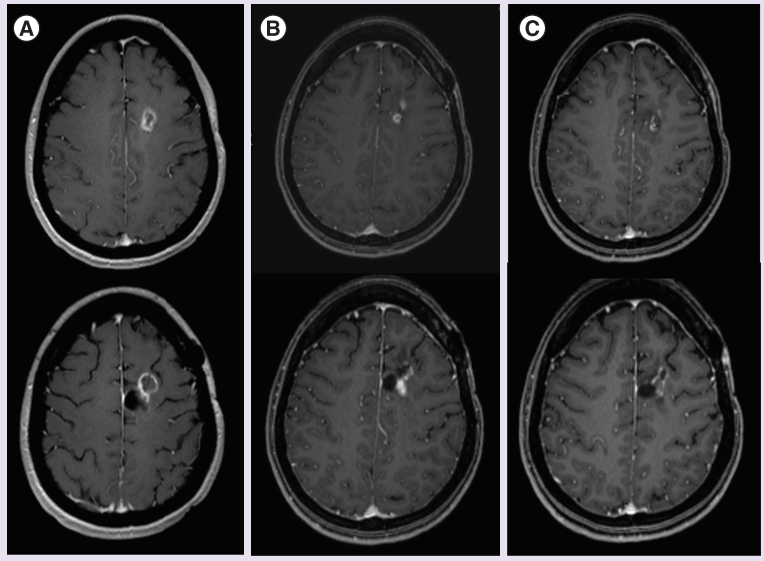

Figure 2. MRI imaging, axial postgadolinium T1-weighted imaging. Baseline brain MRI images **(A)** before starting ivosidenib demonstrated post-LITT changes in the inferior aspect of the surgical cavity in the high left frontal lobe. Brain MRI images at 6 months **(B)** and at 50 months **(C)** postinitiation of ivosidenib demonstrated evolving post-LITT changes with no evidence of tumor recurrence.
LITT: Laser interstitial thermal therapy.

study in patients with advanced solid tumors, including glioma (NCT02073994) [33]. In this study, 66 glioma patients were included and 12 (18.2%) had GBM. Preliminary reports indicated that no dose-limiting toxicities were observed, and the maximum tolerated dose was not reached. The use of ivosidenib in this study was associated with prolonged tumor control and tumor shrinkage in the patients with advanced glioma [33]. Pharmacokinetic and pharmacodynamic data from this study have been previously reported [29]. QT prolongation is a well-known risk associated with ivosidenib. ALT/AST elevations occur in <10% in our glioma Phase I study experience [33]. The patient did not develop any of these toxicities and was able to tolerate the drug for over 4 years with no significant adverse events. This benign toxicity profile in a patient with GBM further supports the safety data provided by hematologic and solid tumor studies where ivosidenib was well tolerated in a heavily pretreated population [21,32,34].

The patient was treated with LITT after biopsy was obtained at the time of progression. Although we are unable to determine whether this treatment influenced the patient's outcome, a recent study reports median OS of 11.8 months and median progression-free survival of 7.3 months for patients with recurrent GBM treated with LITT [35]. In a retrospective review of 13 patients with recurrent GBM, of which 5 (38%) had *IDH1* mutations that were treated with LITT, median progression-free survival was 5 months [36].

A significant body of knowledge has been generated in the last decade that has set the foundation for therapeutic approaches to *IDH*-mutant cancers. Several ongoing trials (NCT04164901, NCT02481154, NCT03343197 and NCT03684811), including a recently initiated pivotal Phase III study of the mIDH1/2 inhibitor vorasidenib in residual or recurrent grade II glioma (NCT04164901), will help to elucidate the precise role of IDH inhibitors as single agents and/or in combination for the treatment of *IDH*-mutant glioma and the best setting (upfront or recurrence) for these drugs.

Author contributions

All of the authors participated in the analysis and interpretation of the data. MI de la Fuente wrote the first draft of the report. All authors contributed to the review and revision of the report and approved the final version for submission.

Acknowledgments

The authors thank the patient and her family, and all who contributed to the completion of this case report.

Summary points

- Overall survival for patients with glioblastoma remains poor despite the multimodality treatment as standard of care.
- A Phase I study of patients with *IDH1*-mutant solid tumors, including glioma, validated mutated IDH as a novel drug target in these settings.
- Treatment with the IDH-mutant inhibitor ivosidenib in our patient has resulted in long-term radiographic disease control and improved seizure control.

Financial & competing interests disclosure

M Lu and L Steelman are employees of and hold stock in Agios Pharmaceuticals, Inc. MI de la Fuente is on advisory boards or has served as consultant for Agios, Puma Biotechnology, Foundation Medicine, and Forma Therapeutics. D Tejera, M Kushnirsky and SH Gultekin have no financial and other competing interests to declare. The Phase I trial in which the patient was enrolled was supported by Agios Pharmaceuticals, Inc. The authors have no other relevant affiliations or financial involvement with any organization or entity with a financial interest in or financial conflict with the subject matter or materials discussed in the manuscript apart from those disclosed.

Medical writing assistance was provided by V Ducas of Excel Medical Affairs, Fairfield, CT, USA, supported by Agios Pharmaceuticals, Inc.

Informed consent disclosure

The patient provided verbal and written informed consent for the inclusion of their medical and treatment history within this case report.

Ethical conduct of research

The study was conducted in accordance with the principles of the Declaration of Helsinki and Good Clinical Practice guidelines and was approved by institutional review boards.

References

Papers of special note have been highlighted as: • of interest; •• of considerable interest

1. Ostrom QT, Gittleman H, Truitt G, Boscia A, Kruchko C, Barnholtz-Sloan JS. CBTRUS statistical report: primary brain and other central nervous system tumors diagnosed in the United States in 2011-2015. *Neuro Oncol.* 20(Suppl. 4), iv1–iv86 (2018).
2. Stupp R, Mason WP, Van Den Bent MJ *et al.* Radiotherapy plus concomitant and adjuvant temozolomide for glioblastoma. *N. Eng. J. Med.* 352(10), 987–996 (2005).
3. Stupp R, Taillibert S, Kanner A *et al.* Effect of tumor-treating fields plus maintenance temozolomide vs maintenance temozolomide alone on survival in patients with glioblastoma: a randomized clinical trial. *JAMA* 318(23), 2306–2316 (2017).
4. Omuro A, Deangelis LM. Glioblastoma and other malignant gliomas: a clinical review. *JAMA* 310(17), 1842–1850 (2013).
5. Sjöblom T, Jones S, Wood LD *et al.* The consensus coding sequences of human breast and colorectal cancers. *Science* 314(5797), 268–274 (2006).
6. Parsons DW, Jones S, Zhang X *et al.* An integrated genomic analysis of human glioblastoma multiforme. *Science* 321(5897), 1807–1812 (2008).
7. Brennan CW, Verhaak RG, Mckenna A *et al.* The somatic genomic landscape of glioblastoma. *Cell* 155(2), 462–477 (2013).
8. Yan H, Parsons DW, Jin G *et al.* IDH1 and IDH2 mutations in gliomas. *N. Eng. J. Med.* 360(8), 765–773 (2009).
9. Amary MF, Bacsi K, Maggiani F *et al.* IDH1 and IDH2 mutations are frequent events in central chondrosarcoma and central and periosteal chondromas but not in other mesenchymal tumors. *J. Pathol.* 224(3), 334–343 (2011).
10. Mardis ER, Ding L, Dooling DJ *et al.* Recurring mutations found by sequencing an acute myeloid leukemia genome. *N. Eng. J. Med.* 361(11), 1058–1066 (2009).
11. Paschka P, Schlenk RF, Gaidzik VI *et al.* IDH1 and IDH2 mutations are frequent genetic alterations in acute myeloid leukemia and confer adverse prognosis in cytogenetically normal acute myeloid leukemia with NPM1 mutation without FLT3 internal tandem duplication. *J. Clin. Oncol.* 28(22), 3636–3643 (2010).

12. Voss JS, Holtegaard LM, Kerr SE *et al.* Molecular profiling of cholangiocarcinoma shows potential for targeted therapy treatment decisions. *Hum. Pathol.* 44(7), 1216–1222 (2013).
13. Louis DN, Perry A, Reifenberger G *et al.* The 2016 World Health Organization classification of tumors of the central nervous system: a summary. *Acta Neuropathol.* 131(6), 803–820 (2016).
14. Ohgaki H, Kleihues P. The definition of primary and secondary glioblastoma. *Clin. Cancer Res.* 19(4), 764–772 (2013).
15. Watanabe T, Nobusawa S, Kleihues P, Ohgaki H. IDH1 mutations are early events in the development of astrocytomas and oligodendrogliomas. *Am. J. Pathol.* 174(4), 1149–1153 (2009).
16. Reitman ZJ, Parsons DW, Yan H. IDH1 and IDH2: not your typical oncogenes. *Cancer Cell* 17(3), 215–216 (2010).
17. Dang L, White DW, Gross S *et al.* Cancer-associated IDH1 mutations produce 2-hydroxyglutarate. *Nature* 462(7274), 739–744 (2009).
18. Losman JA, Kaelin WG Jr. What a difference a hydroxyl makes: mutant IDH, (R)-2-hydroxyglutarate, and cancer. *Genes Dev.* 27(8), 836–852 (2013).
19. Yang H, Ye D, Guan KL, Xiong Y. IDH1 and IDH2 mutations in tumorigenesis: mechanistic insights and clinical perspectives. *Clin. Cancer Res.* 18(20), 5562–5571 (2012).
20. Stein EM, Dinardo CD, Pollyea DA *et al.* Enasidenib in mutant IDH2 relapsed or refractory acute myeloid leukemia. *Blood* 130(6), 722–731 (2017).

- **A Phase I study that illustrates the clinical activity of the IDH2 inhibitor enasidenib in patients with *IDH2*-mutant relapsed or refractory acute myeloid leukemia (AML).**

21. Dinardo CD, Stein EM, De Botton S *et al.* Durable remissions with ivosidenib in IDH1-mutated relapsed or refractory AML. *N. Eng. J. Med.* 378(25), 2386–2398 (2018).

- **A Phase I dose-escalation and expansion study that illustrates the clinical activity of ivosidenib monotherapy in patients with *IDH1*-mutant AML.**

22. Roboz GJ, Dinardo CD, Stein EM *et al.* Ivosidenib induces deep durable remissions in patients with newly diagnosed IDH1-mutant acute myeloid leukemia. *Blood* 135(7), 463–471 (2020).

- **A Phase I study that illustrates the clinical activity of ivosidenib monotherapy in patients with newly diagnosed *IDH1*-mutant AML.**

23. Christians A, Adel-Horowski A, Banan R *et al.* The prognostic role of IDH mutations in homogeneously treated patients with anaplastic astrocytomas and glioblastomas. *Acta Neuropathol. Commun.* 7(1), 156 (2019).

•• **A retrospective analysis that establishes the prognostic role of *IDH* mutations in patients with glioblastomas.**

24. Eckel-Passow JE, Lachance DH, Molinaro AM *et al.* Glioma groups based on 1p/19q, IDH, and TERT promoter mutations in tumors. *N. Eng. J. Med.* 372(26), 2499–2508 (2015).
25. Weller M, Felsberg J, Hartmann C *et al.* Molecular predictors of progression-free and overall survival in patients with newly diagnosed glioblastoma: a prospective translational study of the German Glioma Network. *J. Clin. Oncol.* 27(34), 5743–5750 (2009).
26. Yang P, Zhang W, Wang Y *et al.* IDH mutation and MGMT promoter methylation in glioblastoma: results of a prospective registry. *Oncotarget* 6(38), 40896–40906 (2015).
27. Brown PD, Krishnan S, Sarkaria JN *et al.* Phase I/II trial of erlotinib and temozolomide with radiation therapy in the treatment of newly diagnosed glioblastoma multiforme: North Central Cancer Treatment Group study N0177. *J. Clin. Oncol.* 26(34), 5603–5609 (2008).
28. Omuro A, Vlahovic G, Lim M *et al.* Nivolumab with or without ipilimumab in patients with recurrent glioblastoma: results from exploratory Phase I cohorts of CheckMate 143. *Neuro Oncol.* 20(5), 674–686 (2018).
29. Fan B, Mellinghoff IK, Wen PY *et al.* Clinical pharmacokinetics and pharmacodynamics of ivosidenib, an oral, targeted inhibitor of mutant IDH1, in patients with advanced solid tumors. *Invest. New Drugs* 38(2), 433–444 (2020).

•• **Clinical pharmacokinetic and pharmacodynamic analyses that illustrate the good exposure and long half-life of ivosidenib in patients with *IDH1*-mutant solid tumors.**

30. Hansen E, Quivoron C, Straley K *et al.* AG-120, an oral, selective, first-in-class, potent inhibitor of mutant IDH1, reduces intracellular 2HG and induces cellular differentiation in TF-1 R132H cells and primary human IDH1 mutant AML patient samples treated *ex vivo*. *Blood* 124(21), 3734 (2014).
31. Nicolay B, Narayanaswamy R, Aguado E *et al.* EXTH-59. The IDH1 mutant inhibitor AG-120 shows strong inhibition of 2-HG production in an orthotopic IDH1 mutant glioma model *in vivo*. *Neuro Oncol.* 19(Suppl. 6), vi86–vi86 (2017).
32. Mellinghoff IK, Cloughesy TF, Wen PY *et al.* A Phase I, open label, perioperative study of AG-120 and AG-881 in recurrent IDH1 mutant, low-grade glioma: results from cohort 1. *J. Clin. Oncol.* 37(Suppl. 15), 2003–2003 (2019).

•• **A perioperative study in patients with nonenhancing gliomas that establishes the inhibitory activity of ivosidenib against the mutant IDH1 enzyme in these tumors.**

33. Mellinghoff IK, Ellingson BM, Touat M *et al.* Ivosidenib in isocitrate dehydrogenase 1-mutated advanced glioma. *J. Clin. Oncol.* doi:10.1200/JCO.19.03327 (2020) (Epub ahead of print).

•• **A Phase I study that establishes the tolerability and clinical activity of ivosidenib in patients with *IDH1*-mutant advanced glioma.**

34. Lowery MA, Burris HA 3rd, Janku F *et al.* Safety and activity of ivosidenib in patients with IDH1-mutant advanced cholangiocarcinoma: a Phase I study. *Lancet Gastroenterol. Hepatol.* 4(9), 711–720 (2019).

- **A Phase I study that illustrates the tolerability and clinical activity of ivosidenib in patients with *IDH1*-mutant cholangiocarcinoma.**

35. Kamath AA, Friedman DD, Akbari SHA *et al.* Glioblastoma treated with magnetic resonance imaging-guided laser interstitial thermal therapy: safety, efficacy, and outcomes. *Neurosurgery* 84(4), 836–843 (2019).

36. Thomas JG, Rao G, Kew Y, Prabhu SS. Laser interstitial thermal therapy for newly diagnosed and recurrent glioblastoma. *Neurosurg. Focus* 41(4), E12 (2016).